



# Surgical Management of Bell's Palsy

Bruce J. Gantz, MD; Jay T. Rubinstein, MD, PhD; Paul Gidley, MD; George G. Woodworth, PhD

**Objectives:** Incomplete return of facial motor function and synkinesis continue to be long-term sequelae in some patients with Bell's palsy. The aim of this report is to describe a prospective study in which a well-defined surgical decompression of the facial nerve was performed in a population of patients with Bell's palsy who exhibit the electrophysiologic features associated with poor outcomes. In addition, management issues related to Bell's palsy including herpes simplex virus type 1 etiology, the natural history, electrodiagnostic testing, and efficacy of surgical strategies are reviewed. **Study Design and Methods:** A multicenter prospective clinical trial was designed utilizing electroneurography (ENOG) and voluntary electromyography (EMG) to identify patients with Bell's palsy who would most likely develop poor return of facial function, as suggested by Fisch and Esslen. Patients who displayed electrodiagnostic features of poor outcome, >90% degeneration on ENOG testing and no voluntary motor unit EMG potentials within 14 days of onset of total paralysis, were offered a surgical decompression of the facial nerve through a middle cranial fossa surgical exposure, including the tympanic segment, geniculate ganglion, labyrinthine segment, and meatal foramen. Control subjects were those who displayed similar electrodiagnostic features and time course. **Results:** Subjects who did not reach 90% degeneration on ENOG within 14 days of paralysis all returned to House-Brackmann grade I (n=48) or II (n=6) at 7 months after onset of the paralysis. Control subjects self-selecting not to undergo surgical decompression when >90% degeneration on ENOG and no motor unit potentials on EMG were identified had a 58% chance of developing a poor outcome at 7 months after onset of paralysis (House-Brackmann grade III or IV [n=19]). A group with similar ENOG and EMG findings undergoing

middle fossa facial nerve decompression exhibited House-Brackmann grade I (n=14) or II (n=17) in 91% of the cases. An exact permutation test confirmed that the surgical group had a significantly higher proportion of patients with a good outcome (House-Brackmann grade I or II) ( $P = .0002$ ). **Conclusion:** Electroneurography in combination with voluntary EMG successfully identified patients who will most likely return to normal from those who had a greater chance of long-term sequelae from Bell's palsy. Surgical decompression medial to the geniculate ganglion significantly improves the chances of normal or near-normal return of facial function in the group that has a high probability of a poor result. Surgical decompression must be performed within 2 weeks of onset of total paralysis for it to be effective. **Key Words:** Surgical decompression, facial nerve, Bell's palsy, prospective clinical trial, electroneurography.

*Laryngoscope*, 109:1177-1188, 1999

## INTRODUCTION

Spirited debate among prominent clinicians has dominated the discussion of the management of Bell's palsy for more than 60 years. Extremes of opinion continue to range from those who believe surgical decompression is mismanagement<sup>1</sup> to those who advocate early decompression for all patients with total paralysis.<sup>2,3</sup> Medical management with steroids or other medications has also been controversial. The clinician remains confused regarding the appropriate management of the patient who presents with the emotional and physical trauma associated with an episode of acute facial paralysis due to Bell's palsy.

Fundamental to management issues of this disorder is the question of the etiology of Bell's palsy. Fortunately, the etiology of "idiopathic" facial paralysis is becoming clearer. Recent studies by Murakami et al.<sup>4</sup> strongly suggest that herpes simplex virus type 1 (HSV-1) is active in idiopathic facial paralysis. Eleven of 14 patients with Bell's palsy who underwent facial nerve decompression during the acute phase of the disorder displayed DNA fragments of HSV-1 in perineurial fluid from the nerve. Perineurial fluid in these subjects was negative for herpes zoster (HZ) DNA and decompression control subjects had neither HSV-1 nor HZ in their perineurial facial nerve fluid. An Iowa group<sup>5</sup> has also identified HSV-1 DNA in a temporal bone section of a pa-

Presented as a Candidate's Thesis (B.J.B.) to the American Laryngological, Rhinological and Otological Society, Inc.

From the Department of Otolaryngology—Head and Neck Surgery (B.J.G., J.R., P.G.) and the Department of Statistics and Actuarial Science (G.G.W.), University of Iowa College of Medicine, Iowa City, Iowa.

Editor's Note: This Manuscript was accepted for publication May 27, 1999.

Send Reprint Requests to Bruce J. Gantz, MD, Professor and Head, Department of Otolaryngology 190 Head and Neck Surgery, The University of Iowa Hospitals and Clinics, 200 Hawkins Drive, Iowa City IA 52242, U.S.A.

tient dying 6 days after developing Bell's palsy. These two independent pieces of evidence strongly support the concept that the facial paralysis associated with Bell's palsy is the result of a viral inflammatory response that induces edema within the facial nerve. An animal model for Bell's palsy has recently been developed by inoculating herpes simplex virus into the auricles or tongues of mice.<sup>6</sup> Transient facial paralysis occurred 6 to 9 days after inoculation. Histopathologic analysis of the involved nerves demonstrated diffuse edema and inflammatory infiltrates, and HSV antigens were detected in the geniculate ganglion. Additional evidence that a viral etiology is active in Bell's palsy is provided by the improved clinical outcome when an antiviral agent was added to the treatment regimen. A double blind prospective clinical trial testing prednisone versus prednisone and acyclovir in patients with Bell's palsy demonstrated an improved outcome when patients received acyclovir.<sup>7</sup>

The above studies offer more than circumstantial support for a herpes simplex viral cause of Bell's palsy first postulated by McCormick in 1972.<sup>8</sup> In fact, in a recent review of the etiology of Bell's palsy, Schirm and Mulkens<sup>9</sup> stated that the Murakami study<sup>4</sup> was "So well-controlled that it provides conclusive evidence that reactivation of HSV genomes from the geniculate ganglia is the most important cause of Bell's palsy." Steroids and antiviral medication are appropriate management strategies for the acute phase of the disease. The majority of patients will completely resolve their paralysis and are left with no residual deficits; however, a small number of patients do not return to normal health. This group is bothered by asymmetric facial movements and troubling synkinesis. The Adour acyclovir trial<sup>7</sup> documented that a poor facial function recovery (House-Brackmann grade III or IV) occurred in 23% of the prednisone-only treatment group and 7% of the prednisone + acyclovir group. An important point to consider in this report is the fact that the characteristics of the patient population described are quite different from the usual populations described in other studies.<sup>10,11</sup> Eighty percent of the individuals in this study had symptoms of facial paresis only and 20% of patients developed complete paralysis during the study. None of the patients exhibited a complete loss of nerve excitability during the acute phase of the paralysis. Most studies of Bell's palsy include a number of patients that exhibit loss of nerve stimulability, and the majority of these have total paralysis. Unfortunately, the electrophysiologic test results are not described for the two treatment groups. The study does point out however that regardless of the medical management, some patients will have a poor outcome with incomplete return of facial movement and bothersome synkinesis.

The issues that continue to trouble the clinician treating a patient with Bell's palsy are 1) how does one identify patients who will be left with a poor outcome (poor return of facial motion—House-Brackmann grade III or worse)? 2) can poor outcomes be prevented by surgical decompression? and 3) if so, is the timing of the surgical decompression critical? This article analyzes the natural history, discusses electrodiagnostic strategies, and reviews the past history of surgical management of Bell's palsy. It also describes a study in which a well-defined surgical decompression of the facial nerve was performed in a population of

patients with Bell's palsy who exhibit electrophysiologic features known to result in poor outcomes.

## LITERATURE REVIEW

### *Natural History*

Bell's palsy has been described as idiopathic, acute, unilateral, lower motor neuron facial paresis or paralysis in which no other etiology, such as infection, neoplasm, or trauma, can be identified. Most authors limit the disease to involve only the seventh cranial or facial nerve. Some expand the definition of Bell's palsy to include patients who have facial nerve dysfunction and other cranial nerve neuropathies (cranial nerve polyneuropathy) such as trigeminal, glossopharyngeal, and vestibular symptoms.<sup>12,13</sup>

Several studies containing more than 1,000 patients each have documented the natural history of Bell's palsy.<sup>10,11,13</sup> The Peitersen article is unique as it evaluates the spontaneous course of the disease without medical or surgical intervention.<sup>10</sup> Idiopathic facial paralysis occurred in every decade of life, with a mean age of between 40 and 44 years. It was less common before the age of 15 and after the age of 60 years. The incidence in men and women was similar. Between 6% and 9% had a previous history of facial paralysis. Facial paresis alone occurred in 31%, while the remainder had total unilateral paralysis. Other common symptoms included postauricular pain, dysgeusia, reduced lacrimation, and phonophobia. Diabetes was present in 2.5% of subjects in the Devriese study<sup>11</sup> and 12.5% of the Adour patient population,<sup>13</sup> and functional recovery was poorer in the diabetic group.

Nerve excitability studies in the Danish study<sup>11</sup> revealed that if nerve excitability remained normal, 80% of treated and untreated patients recovered normal motor function, and 20% had a "slight paresis." A "diminished excitability" resulted in 25% normal, and 67% slight paresis. When nerve excitability was lost, hardly any of the patients returned to normal and about half had a distinct long-term paresis. Peitersen concluded that normal facial function was restored in 71% of patients while 16% exhibited permanently diminished function with contracture and associated movements.<sup>10</sup> In patients whose recovery was delayed, beginning at 3 months or more after the initial onset of paralysis, all developed sequelae. Subjects more than 60 years of age also had reduced return of function in all three studies.<sup>10,11,13</sup> Return of at least some facial motor function was observed in all patients in all three studies, and none of the patients experienced total permanent paralysis.

An issue common to most of the literature on Bell's palsy is the lack of an accepted facial function recovery reporting system that allows comparison among individual reports. The American Academy of Otolaryngology—Head and Neck Surgery adopted the House-Brackmann facial nerve grading system in 1984.<sup>14</sup> The European literature, along with some authors in this country, continue to report results using private grading scales, which complicates interpretation of results.

### *Electrophysiology*

Bell's palsy induces a wide range of facial muscle movement dysfunction from mild paresis to total paraly-

sis. Individual patients display a spectrum of symptoms: some maintain reduced movement throughout the course of the disorder while others rapidly become totally paralyzed over a 24-hour period. The pathophysiology of the neural injury is suspected to be due to edema within the nerve induced by a viral infection. The animal model developed by Toshiaki et al.,<sup>6</sup> as well as human temporal bone histology from individuals with acute Bell's palsy,<sup>15,16</sup> supports this hypothesis. The size of the fallopian canal and most likely the anatomy of the entrance to the fallopian canal (meatal foramen) and the degree of neural edema may dictate the neural damage in the individual patient. Ge and Spector<sup>17</sup> have determined that the narrowest intratemporal portion of the fallopian canal, mean 0.68 mm, is found at the entrance to the fallopian canal at the lateral aspect of the internal auditory canal. A tight arachnoid band is also found adherent to the nerve in this region, which also contributes to the constriction at this point. It should also be kept in mind that the injury that results in a neural conduction block is not an all-or-none phenomenon. In each individual, a range of injury over the course of the disorder can occur within the 10,000 individual nerve fibers. These factors, along with the fact that an electrophysiologic test has not been devised that precisely measures the neural traffic through the site of injury in the temporal bone, complicate prognostic predictions for the individual patient. Transcranial magnetic stimulation of the facial nerve has been proposed as a technique to measure the extent of injury at the site of the conduction block by stimulating proximal to the intratemporal injury.<sup>18,19</sup> Retrograde activation of the facial motor nucleus and measurement of facial nerve evoked potentials is also possible with magnetic stimulation.<sup>20</sup> However, neither test paradigm has been applied to large populations of subjects with facial paralysis and their clinical utility is not known.

Several electrodiagnostic strategies have been devised to evaluate the neural damage following acute facial nerve paralysis. These tests attempt to measure the amount of neural degeneration that has occurred distal to the site of injury by measuring the muscle response to an electrically evoked stimulus. Electrodiagnostic test strategies rely on the physiological premise of neural injury originally describe by Sunderland<sup>21</sup> and Seddon.<sup>22</sup> Injuries that induce only a conduction block within the nerve (neuropraxia) do not disrupt axoplasmic continuity and therefore can continue to conduct a neural discharge if an electrically evoked stimulus is presented distal to conduction block. More severe injuries, axoplasmic disruption (axonotmesis), or neural tubule disruption (neurotmesis) result in Wallerian degeneration distal to the site of the injury. Nerve fibers that undergo Wallerian degeneration cannot propagate electrically generated evoked potentials distal to the injury. Axonotmesis, however, has a better prognostic outcome compared with neurotmesis. If the neural injury resolves in a nerve that has undergone axonotmesis, the axon will regenerate through the intact neural tubule, allowing complete return of motor function to the muscle fiber innervated by that nerve fiber. The more severely disrupted neural tubule injury of neurotmesis might not regenerate successfully and can result in misdirection of fibers, causing synkinesis and incomplete

return of motor function. Electrodiagnostic tests can be used to differentiate nerve fibers that have minor conduction block problems (neuropraxia) from those that have undergone Wallerian degeneration, but these tests cannot differentiate the type of Wallerian degeneration, axonotmesis-type injury from neurotmesis. The rate of progression of Wallerian degeneration after injury can be measured and provides some information about the severity of the degeneration. More rapid Wallerian degeneration is associated with neurotmesis, while nerves that degenerate more slowly are more likely to exhibit axonotmesis.

Esslen<sup>23,24</sup> and Fisch<sup>25-27</sup> popularized the most commonly used electrodiagnostic test for evaluation of acute facial paralysis, electroneurography (ENOG). ENOG uses a maximal electrically evoked stimulus paradigm and recording technique to objectively measure the amplitude of the facial muscle compound action potential.<sup>28</sup> Esslen theorized that the amplitude of the compound muscle action potential, measured from the movement of the facial muscles with a surface electrode, was proportional to the number of blocked nerve fibers (neuropraxic) that could be stimulated. By comparing the paralyzed side of the face with the normal side, an estimate of the amount of the nerve that had degenerated could be determined. Dividing the response of the paralyzed side by the normal side and subtracting from 100% estimates the percentage of fibers that have degenerated. Esslen and Fisch demonstrated that when 95% of the nerve degenerated and became nonstimulable, the degree of facial motor function return was greatly reduced. Those patients reaching 95% degeneration had a 50% chance of an unfavorable recovery.<sup>25,29</sup> The reason patients had a 50/50 chance of good versus poor return was based on the fact that some of the fibers undergo axonotmesis and some demonstrate neurotmesis. When there is a greater percent of neurotmesis, the greater the chance of poor outcome. Patients who maintained at least 10% stimuable fibers during the first 21 days of paralysis all returned to 80% to 100% facial muscle function, which was considered a good outcome on their grading scale.

Timing of Wallerian degeneration is an additional feature of electrodiagnosis that provides important prognostic information. Following complete transection of the facial nerve in traumatic injury, 100% Wallerian degeneration occurs over 3 to 5 days as the distal axon slowly degenerates. On the other hand, in subjects who have a compressive conduction block that produces a delayed paralysis, 100% Wallerian degeneration may be evident 14 to 21 days after paralysis. In the delayed paralysis subject, facial function usually returns to normal, suggesting that axonotmesis is the primary type of degeneration that has occurred. It is between the 6-day and 14-day complete Wallerian degeneration group that the amount of axonotmesis and neurotmesis is unclear. Therefore, timing of Wallerian degeneration is as important as the percent of degeneration on ENOG testing.<sup>27</sup> Figure 1 is modified from Fisch<sup>27</sup> and illustrates the prognostic importance of timing of maximal Wallerian degeneration in acute facial nerve paralysis. This feature of ENOG is also crucial to the issue of using this type of electrophysiologic test for prognostic information in more chronic long-standing facial nerve paresis or paralysis.

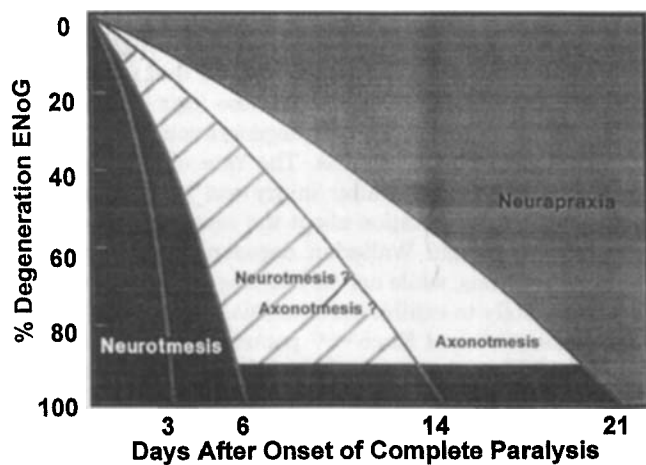


Fig. 1. Time course of neural degeneration (after Fisch).

In chronic conditions, such as facial nerve neuromas, individual nerve fibers undergo simultaneous degeneration and regeneration. Measurement of the compound muscle action potential from the surface requires a synchronous discharge of all stimuable nerve fibers. Regenerating nerve fibers conduct at differing rates, producing dyssynchrony, and result in an overestimate of neural degeneration. It is not uncommon to record no response with the ENOG in subjects with early recovery from Bell's palsy when voluntary movement is observed. It is for this reason that a voluntary EMG recording is always performed when 100% neural degeneration is recorded with ENOG. A needle electrode is placed in the orbicularis oculi and orbicularis oris muscles and the patient is asked to make a voluntary contraction. If motor unit potentials are observed with voluntary contraction during the first 2 weeks after the onset of paralysis, it indicates that early deblocking of the neural conduction block has taken place and a good recovery of facial function will ensue. ENOG is only of value in the acute phase of the injury, between day 3 and 21 after complete loss of voluntary function. EMG is the more useful electrophysiologic test 3 weeks after the onset of complete facial paralysis.

Various studies have independently confirmed the clinical prognostic value of ENOG in acute facial paralysis.<sup>30-34</sup> The Michigan group<sup>31</sup> demonstrated that those individuals who did not degenerate beyond 90% on ENOG testing had normal or near-normal return of facial muscle function. Twenty-five subjects recovered to grade I (normal) House-Brackmann function and 3 others exhibited grade II (near-normal) House-Brackmann return. Coker<sup>35</sup> evaluated different recording electrode placement strategies for ENOG and concluded that recording from the nasolabial fold, using the technique proposed by Esslen with a hand-held carrier (optimal placement technique),<sup>28</sup> and the nasal ala paste-on electrodes proposed by Hughes<sup>36</sup> were similar. Coker<sup>35</sup> did comment that the electrode carrier strategy of Esslen was more sensitive in obtaining potentials in those patients with more severely degenerated facial nerves. In a later study by Coker<sup>35</sup> that attempted to correlate ENOG and the nerve excitability test of Laumans and Jongkees,<sup>37</sup> correlation of the two

tests was not possible. However, it was stated that the optimal placement technique was superior to the standard lead placement strategy. Another aspect of the Coker study<sup>35</sup> was to determine if ENOG amplitude of the compound action potential reflected the amount of degenerated versus functioning nerve fibers. A series of partial transections of the facial nerve in cats was performed. ENOG measures were made and compared with intact axon counts 2 weeks after partial transection. There was a more consistent correlation between axon count and the optimal placement ENOG technique of Esslen compared with the paste-on electrode strategy in the cats.

Electroneurography has been discredited by some owing to test-retest reliability,<sup>38,39</sup> but this can be overcome by performing multiple tests at a given session and taking an average.<sup>35</sup> It is also important to stimulate the nerve at the stylomastoid foramen 10 to 20 times before making an amplitude measurement. The initial stimulation will improve the synchronization within the nerve, which is essential to making an accurate measurement.<sup>24,26,28</sup> As the compound action potential amplitude decreases compared with the normal side of the face, the test-retest variability becomes less of an issue. As the difference between the normal (denominator) and paralyzed sides (numerator) widens, it has a reduced effect on the calculation of the results. The majority agrees that it is the most accurate electrodiagnostic test strategy available for the evaluation of acute phase of facial paralysis.<sup>35,40-43</sup>

### **Surgical Management of Bell's Palsy**

Decompression of the facial nerve as a treatment for Bell's palsy was first reported by Balance and Duel in 1932.<sup>44</sup> Surgical management of Bell's palsy has been controversial since its inception. Fowler commented in 1939 that there was controversy regarding the indications for this procedure and that the procedure should only be performed by experts.<sup>45</sup> An excellent review of the first 50 years of surgical decompression of the facial nerve in Bell's palsy was compiled by Adour and Diamond.<sup>46</sup> They comment that the site of decompression has migrated over 50 years from the distal 1 cm at the stylomastoid foramen<sup>44</sup> to the entrance of the fallopian canal medially<sup>47</sup> and the timing of the procedure has varied from 3 months to immediate onset of total paralysis and reduction of salivary flow.<sup>48</sup> Their review concluded that there was no evidence that surgical decompression provided any improvement over the natural history of the disorder. An additional conclusion of this review was that there was no effective way of identifying early in the disorder the 15% to 25% of patients who would eventually have a poor outcome.

Fisch and Esslen were the first to propose that the most likely site for neural compression and conduction block in Bell's palsy was at the entrance to the meatal foramen, its narrowest point.<sup>47</sup> Intraoperative evoked EMG documented the conduction block at this area in 94% of decompressed cases and bulbous swelling proximal to this point was the usual observation. Fisch further described a series of patients who underwent transmastoid and middle cranial fossa decompression of the descending

and tympanic segments, geniculate ganglion, labyrinthine segment, and meatal foramen if their ENOG degenerated to 90% or more within 21 days of onset of total paralysis.<sup>25,47,48</sup> The decompressed group had a better return of function (79% for those 95%–100% degenerated and 93% for those with 90%–94% degenerated) than those who were not decompressed (64% of normal). The facial nerve recovery grading system used in this study is a combination of the subjective, objective, and detailed evaluation strategies and has not been calibrated to the House-Brackmann scale. The study has been criticized for its small number of subjects. Attempts to replicate this study have not appeared, owing to the technical difficulty of surgery and small number of subjects who require surgical intervention based on the electrophysiologic requirements.

May, an ardent proponent of surgical decompression,<sup>48,49</sup> changed his opinion in 1984 and embraced the position that decompression was of no benefit in Bell's palsy.<sup>50,51</sup> His conclusions were based on a transmastoid decompression of the nerve that included the geniculate ganglion and the distal portion of the labyrinthine segment. The meatal foramen was not decompressed in his population. He did limit his decompression to patients who had complete paralysis and reduction to 25% or less of normal on the Schirmer's test, submandibular salivary flow test, maximal stimulation test, and evoked EMG (a form of ENOG). Of the 38 patients who met these requirements, 25 underwent transmastoid decompression and 13 self-selected no surgical treatment. The results of this study demonstrated that three of the nonsurgical group and five of the surgical group achieved satisfactory results (House-Brackmann facial nerve grade I or II). Ten nonsurgical group (77%) and 18 surgical group (80%) patients had an unsatisfactory result (House-Brackmann grade III or IV) at 6 months' or more follow-up. This study has had a far-reaching impact on the value of surgical decompression in this disorder. Many physicians and surgeons have

questioned the efficacy of *any* surgical procedure in the management of Bell's palsy.

In summary, surgical decompression of the facial nerve in acute Bell's palsy remains controversial because of the following points: issues of patient selection criteria based on electrodiagnostic studies; site of decompression; limited number of patients who require decompression at any single center; and the inability to transfer results from study to study because of the continued use of independent facial function grading systems.

## MATERIALS AND METHODS

A multicenter prospective study that manages patients with Bell's palsy based on the Fisch-Esslen paradigm of ENOG selection criteria and surgical decompression strategy was begun in 1982. Originally 14 neurotologic centers were invited to participate in the study. Three otology/neurotology centers—The University of Iowa, Baylor College of Medicine, and the University of Michigan—were able to enroll more than one subject in the surgical arm of the study and are included in the data analysis.

### Criteria for Enrollment

Patients with Bell's palsy who had total facial paralysis of 3 weeks' duration or less were invited to enroll in the study. The facial paresis must have had an acute onset over 1 day, progressing to total paralysis within 1 week. A complete head and neck history and physical examination and neurologic exam were performed. A past history of diabetes was noted. Laboratory studies included a blood sugar and sedimentation rate, audiogram with stapedal reflex testing, Schirmer's test, and electrodiagnostic tests including ENOG and voluntary EMG if the acute paralysis was more than 3 days' duration. Imaging studies such as computed tomography or magnetic resonance imaging scans were not obtained in subjects who had a typical history of Bell's palsy unless they elected to have a surgical decompression.

### Protocol

Subjects meeting the entrance criteria seen within the first 3 days of onset of facial paralysis were placed on 80 mg of

## Bell's Palsy Management Algorithm

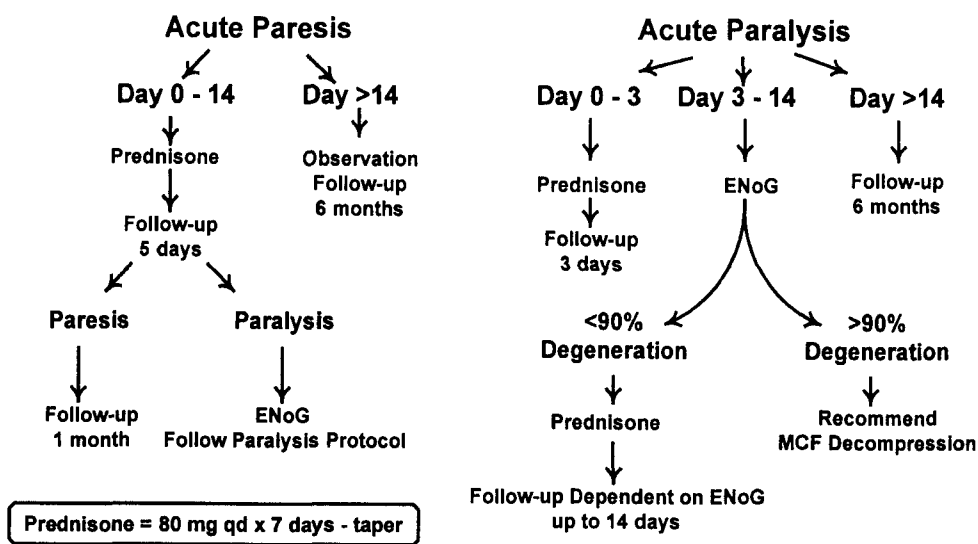


Fig. 2. Bell's palsy management algorithm. ENOG = electroneurography; MCF = middle cranial fossa.

prednisone for 7 days and rapidly tapered over days 8 through 14. See Figure 2 for protocol algorithm.

Patients who were seen after 3 days of total paralysis underwent the ENOG, and voluntary EMG if they demonstrated 100% degeneration on ENOG. ENOG was performed according to Esslen<sup>23,28</sup> using a fixed carrier surface electrode system to perform stimulation and record the compound muscle action potential from the nasolabial fold. The recording electrode was moved to capture the compound action potential with the greatest amplitude. If no compound action potential was recorded from the paralyzed side of the face, a concentric EMG electrode was placed in the orbicularis oculi and orbicularis oris and the patient was asked to make a maximal facial contracture to determine if any facial muscle motor units were active. Presence of voluntary motor unit potentials indicated deblocking and beginning of return of voluntary facial motion.<sup>23,28</sup> If the subject displayed less than 90% neural degeneration on ENOG, he or she was placed on prednisone, if it was within 1 week of paralysis onset. Follow-up was based on the percent of neural degeneration and days since onset of total paralysis (Fig. 3).

If the patient exhibited 90% or more neural degeneration on the paralyzed side compared with the uninvolved side and exhibited no motor unit potentials on voluntary EMG within 14 days of the onset of total paralysis, he or she was offered surgical decompression of the facial nerve through a middle cranial fossa exposure. The internal auditory canal, meatal foramen, labyrinthine segment, geniculate ganglion, and tympanic segment were decompressed in all surgical subjects. For the first few years of the study, up to 21 days after onset of paralysis was considered for decompression. After decompression of the nerve, intraoperative EMG was performed to identify the location of the nerve conduction block.<sup>52</sup> If the conduction block was not identified through the middle fossa exposure, a transmastoid decompression was added. Subjects self-selected to be nonsurgical control subjects by not electing to undergo the risks associated with a craniotomy. A small number of patients were offered surgical decompression 14 days after onset of paralysis early in the study. This group is considered to be a surgical control group because they were decompressed after the 2-week period.

Facial movement outcome analysis was based on the American Academy of Otolaryngology—Head and Neck Surgery Facial Paralysis Grading Scale, originally described by House and Brackmann.<sup>14</sup> The six grades are outlined in Table I. Grade I is normal function and grade II is mild dysfunction characterized by slight weakness noticeable on close inspection and may have slight synkinesis. Grades I and II are considered to be a good result, whereas grades III and IV are unfavorable. Grade III has

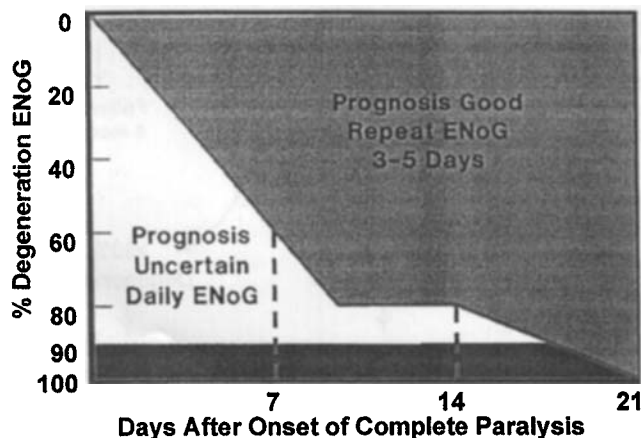


Fig. 3. Electroneurography (ENOG) evaluation protocol.

Grade	Description	Characteristics
I	Normal	Normal facial function in all areas
II	Mild dysfunction	Gross: slight weakness noticeable on close inspection; may have very slight synkinesis At rest: normal symmetry and tone Motion: forehead—moderate to good function; eye—complete closure with minimum effort mouth—slight asymmetry
III	Moderate dysfunction	Gross: obvious but not disfiguring difference between two sides; noticeable but not severe synkinesis; contracture, and/or hemifacial spasm At rest normal symmetry and tone Motion: Forehead—slight to moderate movement; Eye—complete closure with effort; Mouth—slightly weak with maximum effort
IV	Moderately severe dysfunction	Gross: obvious weakness and/or disfiguring asymmetry At rest: normal symmetry and tone Motion: Forehead—none; Eye—incomplete closure; Mouth—asymmetric with maximum effort
V	Severe dysfunction	Gross; only barely perceptible motion At rest: asymmetry Motion: Forehead—none; Eye—incomplete closure; Mouth—slight movement
VI	Total paralysis	No movement

reduced forehead movement, obvious difference between the two sides with noticeable synkinesis, contracture, and/or spasm. Grade IV has no forehead movement, incomplete eye closure, asymmetric mouth with maximal effort, and disfiguring asymmetry. Grade V has minimal movement and grade VI has no movement. Grades V and VI are infrequently encountered in Bell's palsy. Two independent neurologists graded the final outcome at the Iowa Center.

### Statistical Methods

Exact *P* values for all statistics were computed with Mehta's network algorithm using either the FREQ procedure of the Statistical Analysis System (for Pearson correlations) or the PE/EX command of the StatXact software package (SAS Institute, Inc., Cary, NC). Exact *P* values are valid under any distribution of the data (whether normal or nonnormal). Evaluation of exact *P* values involves enumerating all possible configurations of bivariate data with the same univariate distributions as the observed data. The method is computer-intensive.<sup>53</sup>

### RESULTS

The results from The University of Iowa are detailed in this report. Data from the University of Michigan<sup>31</sup> and Baylor<sup>54</sup> have been published separately but are incorporated in the final data analysis, as the subjects were enrolled originally under the protocol outlined above. All three centers used the ENOG strategy outlined by Esslen

and performed voluntary EMG if no response was recorded on the paralyzed side. No voluntary motor unit potentials were present in all subjects undergoing decompression in this series. All subjects underwent decompression of the meatal foramen and labyrinthine segment of the facial nerve through the middle cranial fossa route. While some had combined middle cranial fossa and mastoid decompression, the majority had middle cranial fossa decompression only. Only three patients had a mastoid decompression added to the middle fossa approach in the Iowa series of subjects.

### Iowa Subjects

There were 169 subjects with Bell's palsy evaluated with ENOG at The University of Iowa from 1982 to 1997. More subjects were seen with Bell's palsy, but those with paresis or paralysis of over 2 months' duration were not followed in this database, as they did not undergo ENOG. In this 15-year period, only 30 subjects were available for analysis who had 90% degeneration or more on ENOG within 14 days of the onset of complete paralysis, no voluntary motor unit potentials on EMG, and a follow-up of more than 7 months. A surgical decompression of the meatal foramen, labyrinthine segment, geniculate ganglion, and tympanic segment through a middle cranial fossa exposure was performed on 19 patients, while the other 11 were treated with steroids only. The 11 subjects who met the surgical criteria and elected to be treated with steroids only are nonsurgical controls. The groups self-selected their treatment protocols. A second group of seven subjects, seen between 14 and 28 days after the onset of complete paralysis, displayed 90% or more degeneration on ENOG and had no EMG voluntary motor unit potentials. This group underwent middle cranial fossa decompression early during the study (1982-1985) when subjects up to 21 days after complete paralysis were considered for decompression as originally described by Fisch.<sup>25,29,47</sup> These seven subjects are considered to be a surgical control group, because they were operated on outside the 14-day limit of the protocol. One patient in the less than 14-day group had a mastoid decompression in addition to the middle cranial fossa approach, and two subjects in the more than 14-day group had the combination surgical approach. The outcomes at 7 months' or more follow-up for these 37 subjects are seen in Table II. Three additional subjects underwent surgical decompression but did not return for 6-month follow-up. They are not included in the analysis of data.

TABLE II.  
Iowa Subjects: >90% ENOG Degeneration, No Voluntary EMG Response.

H-B	Steroid Only (Nonsurgical Controls)	MCF <14 days	MCF >14 days (Surgical Controls)
I	0	9	0
II	4	9	2
III	7	1	5
IV	0	0	0

H-B = House-Brackmann grade.

The mean ages of the groups are as follows: steroid-only group: mean age = 47 (range, 23-66 y); less than 14-day decompression group: mean age = 32 years (range, 9-58 y); more than 14-day decompression group: mean age = 41 years (range, 20-57 y). None of the steroid-only or the two surgical group subjects had a diagnosis of diabetes. Surgical complications within the Iowa surgical subjects include a conductive hearing loss of 20 dB in the operated ear (n=1) and cerebrospinal fluid leak treated with temporary lumbar drain (n=1). There were no dead ears, intracranial complications, or other surgical morbidity in the surgical groups. The average hospital stay for a middle cranial fossa craniotomy for facial nerve decompression, vestibular nerve section, or acoustic neuroma at our institution is currently less than 4 days.

The steroid-only nonsurgical control group and the surgical controls (>14-day surgery) displayed similar outcomes. A House-Brackmann grade I was not achieved by any patients in the steroid control or surgical control groups. A House-Brackmann grade II outcome occurred in 4 of 11 of the steroids-only group and 2 of 7 who were operated on after 14 days. A poor return of facial function with obvious facial weakness and obvious synkinesis was observed in 7 of 11 steroid-only and 5 of 7 surgical control subjects. House-Brackmann grade I and II are considered good outcomes, whereas House-Brackmann III and IV are considered poor outcomes.<sup>51</sup> A good outcome was achieved by 33% of the steroid nonsurgical and surgical control groups and a poor outcome occurred in 66%. All of the Iowa patients had some return of forehead motion and none recovered to House-Brackmann grade IV, as seen by other investigators.<sup>51,31</sup>

Patients who underwent a surgical decompression within 14 days of the acute onset of complete facial paralysis achieved an overall better outcome, with nine patients returning to normal (House-Brackmann grade I), nine had House-Brackmann grade II, and only one House-Brackmann grade III. Table III displays individual results of the subjects who underwent middle cranial fossa decompression at Iowa. Both the less than and more than 14-day groups are included. Correlation between the day of decompression after the onset of acute paralysis and House-Brackmann grade at more than 7 months after surgery yielded an R value of 0.74 and a P value of .0001 (Fig. 4). The University of Michigan results using the prescribed protocol are seen in Table IV.<sup>31</sup>

A group of subjects who did not reach 90% degeneration within 2 weeks after the onset of total paralysis were also followed for the first years of the study at Iowa and Michigan.<sup>31</sup> Their outcome at more than 7 months' follow-up are seen in Table V. In this group of subjects 100% had a good outcome (House-Brackmann I or II). Most (48/54; 89%) returned to normal (House-Brackmann grade I). The House-Brackmann grade II group from Iowa had no synkinesis but did have minor weakness on close inspection.

The results of middle cranial fossa decompression within 14 days of onset of the paralysis in subjects with more than 90% degeneration on ENOG and no voluntary motor unit potentials on EMG from the Iowa, Michigan,<sup>31</sup> and Baylor<sup>53</sup> centers are shown in Table VI.



An exact permutation test (stratified by center) confirmed that the surgical group operated on within 14 days contained a significantly higher proportion of patients with a good outcome (House-Brackmann I or II) than did the steroid-only controls. The *P* value for this is .0003 for the Iowa subjects only and .0002 for patients from all three centers.

The surgical decompression group operated on within 14 days from all three centers was also compared with the Iowa and Michigan steroid control groups in Table VII. The Iowa and Michigan nonsurgical control groups were comparable: 36% of the Iowa nonsurgical controls and 45% of the Michigan controls had House-Brackmann grade II, an insignificant difference (*P* = .31, one-sided, Fisher's Exact Test). Similar rates of success (House-Brackmann scores of I or II) were obtained in the surgically decompressed group at Iowa (95%) and Baylor (100%). The observed success rate at Michigan was 78% (95% exact CI: 40%–97%). This did not differ significantly from that for Iowa and Baylor combined (*P* = .16, one-sided, Fisher's Exact Test).

Individuals with Bell's palsy who have 90% or more degeneration on ENOG within the first 14 days of onset of total paralysis, who have no motor unit potentials on voluntary EMG, and undergo a decompression of the meatal foramen, labyrinthine segment, and geniculate ganglion have a 91% chance of a good outcome 7 months after paralysis. Those patients with the same ENOG and EMG parameters who are treated with steroids only have a 42% chance of a House-Brackmann grade I or II outcome. The endpoint facial function recovery difference between surgical decompression performed less than 14 days and steroids-only for this group of patients is significant, with a *P* value of <.0002 on the exact permutation test. All of the Iowa decompression group patients had been treated with steroids by referring physicians before their decompression. The power of this outcome is illustrated in the confidence interval analysis for the Iowa facial nerve decompression subjects illustrated in Figure 5.

## DISCUSSION

Extreme differences of opinion on an issue induce uncertainty about the validity of both points of view. Bell's palsy management is such an issue. All otolaryngologists have experienced the distress of patients who have recovered from Bell's palsy, been treated with steroids, and now seek an opinion 6 months to 1 year later about how to improve their House-Brackmann grade III facial movement. Similar results also can occur when acyclovir is added to the treatment regimen.<sup>7</sup> If all patients recovered to normal or near-normal with medical management after Bell's palsy, other treatments would be unnecessary. Unfortunately, this is not the case. On the other hand, the overwhelming majority of patients who experience Bell's palsy do recover normal or near-normal facial movement.

This study was conceived to address the concept that a specific type of surgical decompression is a useful treatment regimen in a selected population of patients who would have a greater chance of having a poor outcome from Bell's palsy. Patients were separated into those with a good chance to return to normal and those with a greater

TABLE III.  
Individual Outcomes of MCF Decompressions at More Than 7 Months After Surgery (Iowa Subjects).

Day of Surgery After Onset of Acute Paralysis	H-B Grade
4 days (N = 3)	I, I, I
6 days (N = 2)	I, II
7 days (N = 1)	II
9 days (N = 3)	I, I, II
10 days (N = 2)	I, II
11 days (N = 2)	II, II
12 days (N = 1)	I
13 days (N = 2)	I, II
14 days (N = 3)	II, II, III
15 days	II
16 days	III
18 days	III
19 days	II
26 days	III
28 days (N = 2)	III, III

H-B = House-Brackmann.

chance of developing incomplete return of facial movement with synkinesis based on the electrodiagnostic ENOG and voluntary EMG criteria established by Esslen.<sup>24,28</sup> All patients who experienced 90% or less neural degeneration in the first 14 days of onset of total paralysis (54/54) recovered normal facial function (89% House-Brackmann grade I) or near-normal facial function (11% House-Brackmann grade II). ENOG and voluntary EMG, performed using the protocol originally described by Esslen,<sup>24,28</sup> were useful electrodiagnostic strategies to differentiate individuals with Bell's palsy into those who have a favorable prognosis and good outcome and those who had a poor outcome. Our results confirm that ENOG is an effective electrodiagnostic test providing useful prognostic information in the acute phase of Bell's palsy. It is significant that only 32 patients with a diagnosis of Bell's palsy (19% of those with total paralysis seen within 2 mo of onset) displayed the electrodiagnostic features of poor prognosis that would qualify for surgical intervention in a

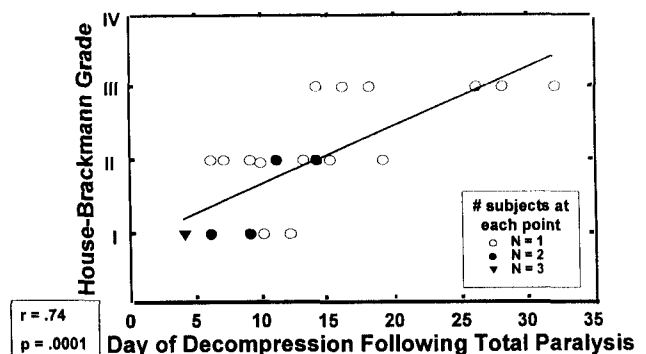


Fig. 4. Bell's palsy. Iowa results (1982–1997): middle cranial fossa decompression. N=26.



TABLE IV.

University of Michigan Bell's Palsy Results: &gt;90% Degeneration ENOG and No Voluntary EMG Potentials.

H-B Grade	No Surgery	Surgical Decompression
I	5	5
II	6	2
III	12	1
IV	4	1

H-B = House-Brackmann.

15-year period at The University of Iowa. This is consistent with the natural history of the disease.<sup>10,11</sup>

Patients with 90% or more neural degeneration on ENOG and no motor unit potentials on voluntary EMG testing were either treated with steroids or underwent surgical decompression of the meatal foramen, labyrinthine segment, and geniculate ganglion of the facial nerve through a middle cranial fossa exposure. It must be stressed that both the medically treated groups at Iowa and Michigan and the surgical groups at Iowa, Michigan, and Baylor had no voluntary motor unit potentials detectable on voluntary EMG testing. Most studies in the literature do not make this important distinction. It is not possible to determine the poor prognostic group with ENOG or nerve excitability testing without performing a voluntary EMG when 100% degeneration or no visual movement is observed. Studies comparing ENOG and nerve excitability testing have failed to recognize this critical issue. It was not uncommon to test patients exhibiting 100% degeneration on ENOG or no movement with maximal stimulation on nerve excitability testing during the first 2 weeks of the paralysis to find a few motor unit potentials with a needle electrode during voluntary contraction. This group has a good prognosis and requires no further therapy.<sup>27</sup> Failing to perform voluntary EMG when electrodiagnostic testing demonstrates 100% neural degeneration invalidates studies comparing surgical decompression and medical management or studies comparing different medical therapies. Subjects who have lost nerve stimulability but have motor unit potentials should be documented, as they will most likely return to normal without further treatment. These subjects should be removed from the poor prognosis group in future studies.

The patients with 90% or more degeneration and no voluntary motor unit potentials on EMG, treated with steroids only, demonstrated 58% (21/36) poor facial func-

TABLE V.

Iowa and Michigan Subjects: &lt;90% Degeneration ENOG.

H-B Grade	Iowa	Michigan	Total
I	23	25	48 (89%)
II	3	3	6 (11%)
III	0	0	0
IV	0	0	0

H-B = House-Brackmann.

tion recovery outcomes (House-Brackmann grade  $\geq$ III). The Iowa and Michigan control groups were comparable, and were similar to the finding originally described by Fisch<sup>55</sup> and Esslen<sup>24</sup> for this group of subjects. Their patients who reached more than 90% degeneration had a 50% chance of recovering normal or near-normal facial movement. The Iowa-Michigan subject pool contained more patients with 100% degeneration than the Zurich study and might account for the larger percentage of poor outcomes.

The group of patients with 90% or more degeneration and no voluntary EMG motor unit potentials who underwent surgical decompression within 14 days displayed distinctly different results from the medically treated group with similar electrophysiologic findings. Surgical decompression of the meatal foramen, labyrinthine segment, and geniculate ganglion within 14 days of total paralysis resulted in 91% House-Brackmann grade I and II results. This result was highly statistically significant using either the Iowa subjects only ( $P = .0003$ ) or combining the surgical results from the three institutions ( $P = .00018$ ) compared with nonsurgical controls. Timing of the surgical decompression was critical. Patients decompressed after 14 days (surgical controls) displayed outcomes similar to nonsurgical controls. The results of the protocol confirm the concept that surgical decompression of the facial nerve medial to the geniculate ganglion is a useful treatment regimen when neural degeneration exceeds 90% on ENOG testing, but the decompression must be performed within 14 days of the onset of total paralysis. The fact that similar results were obtained by three different neurotology centers using the same clinical research paradigm strengthens the clinical significance of the findings. The power of these results is illustrated in the confidence interval analysis for the Iowa facial nerve decompression subjects in Figure 5. The shaded areas are the 95% confidence intervals and the line within the shaded area is the expected probability estimate of achieving a House-Brackmann grade I or II. Even though a small number of subjects underwent middle fossa facial nerve decompression in the present study, this analysis predicts the results if 100 subjects are decompressed when they exhibit similar clinical and electrophysiologic parameters. The chances of achieving a House-Brackmann grade I or II result is extremely high. There is a greater than 93% probability (confidence interval: 62%–99%) that this outcome will occur if decompression is performed by day 12 of the complete paralysis, and at least 82% if done by day 14 (confidence interval: 50%–96%).

Originally Fisch stated that "the destiny of the facial nerve in Bell's palsy is decided within the first 2 to 3 weeks . . ." <sup>29</sup> The results of our study clarify the timing issue. This is reflected in the regression line in Figure 3. If surgical decompression is considered, it should be performed as urgently as possible when more than 90% degeneration is documented but must be performed within the first 14 days of onset of the total paralysis. Some of our patients might have degenerated several days before testing. Unfortunately, we were not able to perform electrodiagnostic studies on every patient daily after the onset of facial paralysis. Some patients who were identified between days 7 and 14 might have displayed more than 90%

TABLE VI.  
Comparison of Steroid-Only Treatment with MCF Decompression Within 14 Days of Onset of Paralysis >90% Degeneration on ENOG and No Voluntary Motor Units on EMG.

H-B	Iowa		Michigan		Baylor	Total	
	Surgery	Steroid	Surgery	Steroid	Surgery	Surgery	Steroid
I	9	0	5	5	0	14	5
II	9	4	2	6	6	17	10
III	1	7	1	12	0	2	19
IV	0	0	1	2	0	1	2

H-B = House-Brackmann grade.

degeneration earlier. The only patient experiencing a grade III outcome in the Iowa surgical group was decompressed on day 14. This patient may have had a better outcome if the severe degeneration was documented earlier. Performing ENOG testing within the first week of the paralysis and following the testing algorithm originally described by Fisch<sup>27</sup> may increase the predictability of ENOG and more precisely determine if the 14-day window is too wide. Primary care physicians, neurologists, and otolaryngologists should be made aware of the need to perform electrical testing on a frequent basis during the first 2 weeks of the acute facial paralysis (between days 3 and 14) to accurately chart the prognosis in cases of Bell's palsy.

It should be noted that in the Iowa group of subjects all but three patients (N=37 surgical and control groups) had maximal 100% degeneration on ENOG. During surgical decompression, the conduction block was identified medial to the geniculate ganglion in 17 of 19 patients using intraoperative evoked EMG.<sup>52</sup> An electrically evoked potential could not be obtained with stimulation of the tympanic segment of the nerve in two patients. A House-Brackmann grade III resulted in one patient; while the other returned to House-Brackmann grade II. This finding suggests that when the ENOG test demonstrates total Wallerian degeneration and there are no voluntary EMG potentials, it does not accurately reflect the exact pathology within the facial nerve. This does not, however, limit the clinical predictive usefulness of ENOG. Rather, it

reflects the inherent problems with any electrodiagnostic test that employs surface stimulation and recording strategies. It is important to note that ENOG is able to prognosticate between favorable and poor return of facial function. Those patients who degenerate more rapidly are the group that develops House-Brackmann grade III or IV facial function. One of the reasons our surgical patients had such favorable outcomes may be because 100% Wallerian degeneration had not actually occurred by the time the surgical decompression was performed. This was documented using intraoperative evoked EMG. The fact that some patients were identified early and decompressed within 1 week of total paralysis (n=6) and the strong correlation ( $r=0.74$ ) between duration of paralysis and outcome (Fig. 3) reinforces this concept.

The medical management of Bell's palsy was not addressed by this protocol, but it appears that the treatment of the acute paresis or paralysis with prednisone and an antiviral agent is most prudent. This study did not include treatment with antiviral medication. If neural degeneration as measured by ENOG and voluntary EMG continues despite the medical management within the first 14 days, surgical decompression of the facial nerve

TABLE VII.  
Surgical Groups from Iowa, Michigan, and Baylor Compared With Nonsurgical Controls From Iowa and Michigan.

H-B Grade	MCF Decompression <14 Days	Steroid Only Controls
I	14	5
II	17	10
III	2	19
IV	1	2
Summary:		
I/II	31 (91%)	15 (42%)
III/IV	3 (9%)	21 (58%)
Total	34	36

H-B = House-Brackmann.

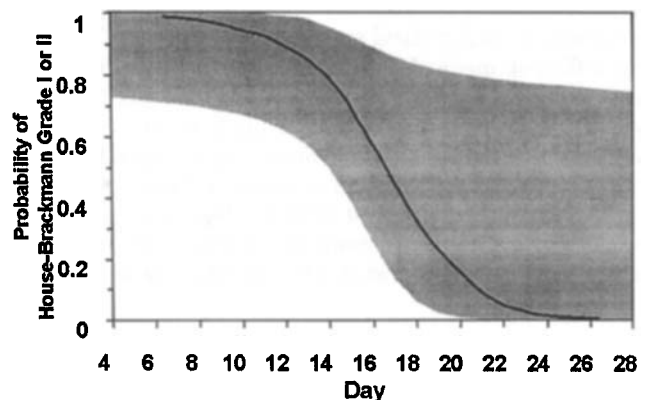


Fig. 5. Expected outcome and 95% confidence interval. Estimated probability of achieving grades I or II as a function of day. The solid line is the estimated probability that a patient will achieve House-Brackmann grade I or II. The shaded region is the 95% confidence interval on the estimated probability. Estimates were calculated from the data in Table II by two-parameter logistic regression (SAS for Windows, version 7.00). These estimates are not sensitive to model specification; adding a quadratic term does not improve the fit, nor does expressing time on the log scale.

through the middle cranial fossa exposure is justified. The risks of surgical decompression, the surgical difficulty, and the experience of the surgeon must be explained to the patient. The importance of "good versus poor" facial nerve recovery must be determined by the patient. Most poor recovery is usually House-Brackmann grade III and rarely House-Brackmann grade IV. Many patients may be satisfied with this type of return, but they need to know that once recovery has taken place, improvement to normal is not possible at a later date. The fact that 42% of patients with ENOG features of poor prognosis did recover normal or near-normal facial function without surgical decompression must be disclosed. Surgical decompression medial to the geniculate ganglion in a group with similar electrophysiologic features, however, significantly enhances the chance of a normal or near-normal facial function recovery to 91%.

## CONCLUSION

The original questions posed have been answered by this study: 1) ENOG is effective in differentiating patients with Bell's palsy into those who have an excellent prognosis from those who might have a poor return of facial movement. All patients who did not reach more than 90% degeneration in the first 2 weeks recovered normal or near-normal facial function. The electrodiagnostic testing must be performed early, during the acute phase of the paralysis, and repeated, dependent on the degeneration, during the first 2 weeks. 2) Review of the literature demonstrates that poor outcomes continue to occur with all available medical regimens. 3) Patients have a 50% to 58% chance of a poor facial function recovery if they reach 90% neural degeneration and have no voluntary EMG motor unit potentials within 14 days of the onset of paralysis. Facial muscle function recovery of this group is significantly improved by performing a facial nerve decompression that includes the meatal foramen, labyrinthine segment, and geniculate ganglion through a middle cranial fossa exposure. Facial movement recovered to normal, or near normal, in 91% of this group with decompression. 4) Timing of surgical decompression is critical. It should be performed as an urgent procedure when more than 90% degeneration is identified. Patients identified with severe degeneration 14 days or more after paralysis should not undergo decompression. Late decompression is of no benefit in Bell's palsy. Previous studies that evaluated the efficacy of surgical decompression in Bell's palsy and did not include decompression of the nerve medial to the geniculate ganglion to the internal auditory canal should not be generalized to support the notion that surgical decompression is not effective in this disorder.

## ACKNOWLEDGMENT

The authors would like to acknowledge John Kemink (deceased), John Niparko, Paul Kileny (The University of Michigan), and Newton Coker (Baylor College of Medicine) for continuing the prospective protocol at their institutions.

## BIBLIOGRAPHY

1. Adour KK. Combination treatment with acyclovir and prednisone for Bell palsy. *Arch Otolaryngol Head Neck Surg* 1988;124:824.
2. Pulec J. Management of Bell's palsy, panel discussion, In: Fisch U, ed, *Facial Nerve Surgery*. Amstelveen, The Netherlands: Kügler Medical Publications; 1977: 392.
3. Pulec J. Early decompression of the facial nerve in Bell's palsy. *Ann Otol Rhinol Laryngol* 1981;90:570-577.
4. Murakami S, Mizobuchi M, Nakashiro Y, Doi T, Hato N, Yanagihara N. Bell's palsy and herpes simplex virus: identification of viral DNA in endoneurial fluid and muscle. *Ann Intern Med* 1996;124:27-30.
5. Burgess RC, Michaels L, Bales JF Jr, Smith RJH. Polymerase chain reaction amplification of herpes simplex viral DNA from the geniculate ganglion of a patient with Bell's palsy. *Ann Otol Rhinol Laryngol* 1994;103(10):775-779.
6. Toshiaki S, Murakami S, Yanagihara N, Fujiwara Y, Hirata Y, Kurata T. Facial nerve paralysis induced by herpes simplex virus in mice: an animal model of acute and transient facial paralysis. *Ann Otol Rhinol Laryngol* 1995;104: 574-581.
7. Adour KK, Buboyannes JM, Von Doereten PG, Byl FM, Trent CS, Quesenberry CP Jr, Hitchcock T. Bell's palsy treatment with acyclovir and prednisone compared with prednisone alone: a double blind, randomized, controlled trial. *Ann Otol Rhinol Laryngol* 1996;105:371-398.
8. McCormick DP. Herpes-simplex virus as cause of Bell's palsy. *Lancet* 1972;1:937-939.
9. Schirm J, Mulken PSJZ. Bell's palsy and herpes simplex virus. *APMIS* 1997;105:815-823.
10. Peitersen E. The natural history of Bell's palsy. *Am J Otol* 1982;4(2):107-111.
11. Devriese PP, Schumacher T, Scheide, A, DeJongh, RH, Houtkooper, JM. Incidence, prognosis and recovery of Bell's palsy. *Clin Otolaryngol* 1990;15:15-7.
12. Adour KK. Cranial polyneuritis and Bell palsy. *Arch Otolaryngol Head Neck Surg* 1976;102(5):262-264.
13. Adour KK, Byl FM, Hilsinger RL Jr, Kahn ZM, Sheldon MI. The true nature of Bell's palsy: analysis of 1000 consecutive patients. *Laryngoscope* 1978;89:787-801.
14. House JW, Brackmann DE. Facial nerve grading system. *Otolaryngol Head Neck Surg* 1985;93:146-147.
15. O'Donoghue GM, Michaels L. Histopathological aspects of Bell's palsy. In: Portmann M, ed. *Proceedings of the 5th International Symposium on the Facial Nerve*. New York: Masson; 1985.
16. Liston SL, Kleid MS. Histopathology of Bell's palsy. *Laryngoscope* 1989;99:23-26.
17. Ge XX, Spector GJ. Labyrinthine segment and geniculate ganglion of facial nerve in fetal and adult human temporal bones. *Ann Otol Rhinol Laryngol* 1981;90(suppl 85):1-12.
18. Schrieffer TN, Mills KR, Murray NMF, Hess CW. Evaluation of proximal facial nerve conduction by transcranial magnetic stimulation. *J Neurosurg* 1988;51:60-66.
19. Benecke R, Meyer BU, Schoenle P, Conrad B. Transcranial magnetic stimulation of the human brain: responses in muscles supplied by cranial nerves. *Exp Brain Res* 1988; 71:621-632.
20. Haghighi S, Estrem SA. Estimation of facial nerve conduction time by orthograde electrical stimulation of the motor cortex. *Electroencephalogr Clin Neurophysiol* 1990;75:82-87.
21. Sunderland S. *Nerve and Nerve Injuries*, edn 2, Edinburgh: E & S Livingstone Ltd.; 1968:31-60,263-273
22. Seddon HJ. Three types of nerve injury. *Brain* 1943;66: 237-288.
23. Esslen E. Electrodiagnosis of facial palsy. In: *Surgery of the Facial Nerve*. Miehke A, ed. Philadelphia: WB Saunders; 1973:45-51.
24. Esslen E. *The Acute Facial Palsies*. Berlin, Heidelberg, New York: Springer-Verlag; 1977.
25. Fisch U. Total facial nerve decompression and electroneurography. In: Silverstein H, Norrel H, eds. *Neurological Surgery of the Ear*. Birmingham, AL: Aesculapius; 1977:21-33.

26. Fisch U. Maximal nerve excitability testing vs. electroneurography. *Arch Otolaryngol* 1980;106:352-357.
27. Fisch U. Prognostic value of electrical tests in acute facial paralysis. *Am J Otol* 1984;5:494-498.
28. Gantz BJ, Gmur AA, Holliday M, Fisch U. Electroneurographic evaluation of the facial nerve: method and technical problems. *Ann Otol Rhinol Laryngol* 1984;93:394-398.
29. Fisch U. Surgery for Bell's palsy. *Arch Otolaryngol* 1981;107:1-11.
30. Thomander L, Stalberg E. Electroneurography in the prognostication of Bell's palsy. *Acta Otolaryngol (Stockh)* 1981;92:221-237.\*\*
31. Stillman JS, Niparko JK, Lee SS, Lileny PR. Prognostic value of evoked and standard electromyography in acute facial paralysis. *Otolaryngol Head Neck Surg* 1992;107:377-381.
32. May M, Blumenthal F, Klein SR. Acute Bell's palsy: prognostic value of evoked electromyography, maximal stimulation, and other electrical tests. *Am J Otol* 1983;5:1-7.
33. Gavilan B, Gavilan C, Sarria MJ. Facial electroneurography: results on normal humans. *J Laryngol Otol* 1985;99:1085-1088.
34. Kartush JM, Lilly DJ, Kemink JL. Facial electroneurography: clinical and experimental investigations. *Otolaryngol Head Neck Surg* 1985;93:516-523.
35. Coker, NJ. Facial electroneurography: analysis of techniques and correlation with degenerating motoneuron. *Laryngoscope* 1992;102:747-759.
36. Hughes GB, Josey AF, Glasscock ME, et al. Clinical electroneurography: statistical analysis of controlled measurements in twenty-two normal subjects. *Laryngoscope* 1981;91:1834-1846.
37. Laumans EPJ, Jongkees LBW. On the prognosis of facial paralysis of endotemporal origin. *Ann Otol Rhinol Laryngol* 1963;72:894-899.
38. Adour, KK, Sheldon, MI, Zahn, ZM. Comparative prognostic value of maximal nerve excitability testing (NET) versus neuromyography (NMG) in patients with facial paralysis. *Trans Pac Coast Otoophthalmol Soc* 1977;58:29-42.
39. Adour, KK, Sheldon, MI, Zahn, ZM. Maximal nerve excitability testing versus neuromyography: prognostic value in patients with facial paralysis. *Laryngoscope* 1980;90:1540-1547.
40. Coker NJ, Fordice JO, Moore S. Correlation of the nerve excitability test and electroneurography in acute facial paralysis. *Am J Otol* 1992;2:127-133.
41. May M, Blumenthal F, Klein SR. Acute Bell's palsy: prognostic value of evoked electromyography, maximal stimulation, and other electrical tests. *Am J Otol* 1983;5:1-7.
42. May M, Klein S, Blumenthal F. Evoked electromyography and idiopathic facial paralysis. *Otolaryngol Head Neck Surg* 1983;91:678-685.
43. Hughes G. Practical management of Bell's palsy. *Otolaryngol Head Neck Surg* 1990;102:658-663.
44. Balance C, Duel AB. The operative treatment of facial palsy: by the introduction of nerve grafts into the fallopian canal and by other intratemporal methods. *Arch Otolaryngol* 1932;15:1-70.
45. Fowler EP Jr. The management and treatment of afflictions of the facial nerve within the fallopian canal. *Acta Otolaryngol* 1939;27:615-625.
46. Adour KK, Diamond C. Decompression of the facial nerve in Bell's palsy: a historical review. *Otolaryngol Head Neck Surg* 1982;90:453-460.
47. Fisch U, Esslen E. Total Intratemporal exposure of the facial nerve. *Arch Otolaryngol* 1972;95:335-341.
48. May M, Hawkins CD. Bell's palsy: results of surgery; salivation test versus nerve excitability test as a basis of treatment. *Laryngoscope* 1972;82:1337-1348.
49. May M, Blumenthal F, Taylor FH. Bell's palsy: surgery based upon prognostic indications and results. *Laryngoscope* 1981;91:2092-2103.
50. May M, Klein SR, Taylor FH. Indications for surgery for Bell's palsy. *Am J Otol* 1984;5:503-512.
51. May M, Klein SR, Taylor FH. Idiopathic (Bell's) facial palsy: natural history defies steroid or surgical treatment. *Laryngoscope* 1985;95:406-409.
52. Gantz BJ, Gmur A, Fisch U. Intraoperative evoked electromyography in Bell's palsy. *Am J Otolaryngol* 1982;3:273-278.
53. Mehta CR. The exact analysis of contingency tables in medical research. *Stat Methods Med Res* 1994;3(2):135-156.
54. Marsh MA, Coker NJ. Surgical decompression of idiopathic facial palsy. *Otolaryngol Clin North Am* 1991;24(3):675-689.
55. Fisch U. Diagnostic studies on idiopathic facial palsy, In: Shambaugh GE, Shea JJ, eds. *Proceedings of the Shambaugh Fifth International Workshop on Middle Ear and Fluctuant Hearing Loss*. Huntsville, AL: Strode Publishing Inc.;1977:219-224.